



# Arthroscopy-Assisted Reconstruction of the Coracoclavicular and Acromioclavicular Ligaments Using a Tendon Graft and Knot-Hiding Clavicular Implants in Chronic Acromioclavicular Separations

Juha O. Ranne, M.D., Ph.D., Severi O. Salonen, B.M., and Janne T. Lehtinen, M.D., Ph.D.

**Abstract:** The purpose of this study is to introduce an arthroscopy-assisted technique to treat chronic acromioclavicular (AC) dislocation. The method involves reconstructing both the coracoclavicular (CC) and AC ligaments in a practical and reliable way using a semi-tendon graft and knot-hiding implants. In the CC reconstruction, the anterior graft limb replaces the trapezoid ligament, whereas the dorsal limb is wrapped around the dorsal edge of the clavicle to reconstruct the conoid ligament. One 5.5-mm drill hole is needed in the clavicle since the semitendinosus graft and the interconnecting supportive suture share the same drill hole. A 2.4-mm drill hole through the coracoid is needed for the interconnective suture. The technique uses knot-hiding titanium implants that are designed to be used with a tendon graft. After finishing the arthroscopic CC reconstruction, the dorsal end of the tendon graft is openly taken over the AC joint to openly reconstruct the superior AC ligament. The AC capsule is then plicated over the reconstruction. The arthroscopic part of the reconstruction is not technically difficult for an experienced arthroscopic shoulder surgeon. For success, it is essential to achieve a tension-free reduction of the distal clavicle and to provide sufficient recovery time postoperatively.

The operative treatment of chronic acromioclavicular (AC) separation has been a difficult task for years, and no established solution has emerged. The longevity and stability of the reconstructions have been the main problem.<sup>1</sup> Other troubles have included difficult operation techniques, awkward implants, wound-healing problems, and unsatisfactory esthetic outcomes.

The clavicle is the only rigid connection of the entire upper extremity to the central skeleton, and insufficiency of the distal clavicle may lead to biomechanical problems and scapular dyskinesia.<sup>2</sup> Therefore, stable reconstruction of an unstable distal clavicle is important for humeroscapular biomechanics. One important element for a sustainable reconstruction is the use of a tendon graft to replace torn ligaments. Coracoclavicular (CC) reconstruction using a tendon graft has clearly been shown to have greater strength than simple suture fixations.<sup>3,4</sup>

This study presents an arthroscopy-assisted technique that has evolved based on studies by Ranne et al.<sup>5</sup> Both the CC ligament complex and AC joint capsule and ligament were reconstructed. The CC ligament reconstruction was conducted arthroscopically, and the AC ligament reconstruction was carried out openly. Knot-hiding titanium implants designed for use with a tendon graft were chosen because it has been shown that protruding suture knots may cause discomfort for the patient or even wound complications.<sup>6</sup> The purpose of this study is to introduce the arthroscopy-assisted technique, where a chronic AC dislocation is treated by reconstructing both the CC and AC ligaments in a practical and reliable way using a tendon graft and

From the Sports Trauma Research Unit, Hospital Mehiläinen Neo, Turku (J.O.R.); The Paavo Nurmi Centre, Department of Physical Activity and Health, the University of Turku, Turku (J.O.R., S.O.S.); and Department of Orthopaedics and Traumatology, Tampere University Hospital, Tampere (J.T.L.), Finland.

The authors report the following potential conflicts of interest or sources of funding: J.O.R. is the inventor of the technique and the CC-Clip implants. Full ICMJE author disclosure forms are available for this article online, as supplementary material.

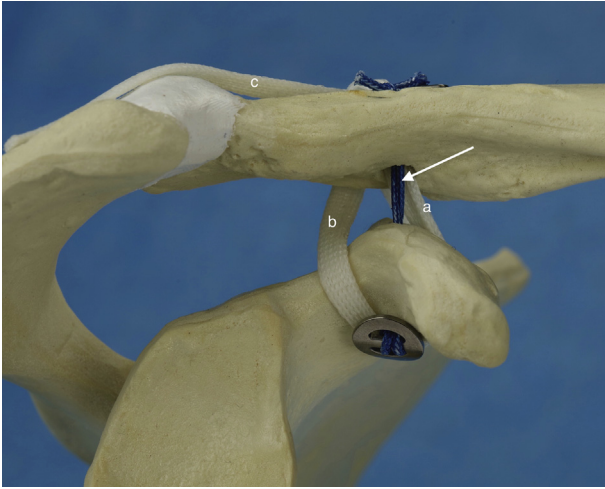
Received August 25, 2020; accepted October 30, 2020.

Address correspondence to Juha O. Ranne, M.D., Ph.D., Hospital Mehiläinen Neo, Joukahaisenkatu 6, 20520 Turku, Finland. E-mail: [rannejuha@gmail.com](mailto:rannejuha@gmail.com) or [juha.ranne@utu.fi](mailto:juha.ranne@utu.fi)

© 2020 by the Arthroscopy Association of North America. Published by Elsevier. This is an open access article under the CC BY-NC-ND license (<http://creativecommons.org/licenses/by-nc-nd/4.0/>).

2212-6287/201470

<https://doi.org/10.1016/j.eats.2020.10.077>

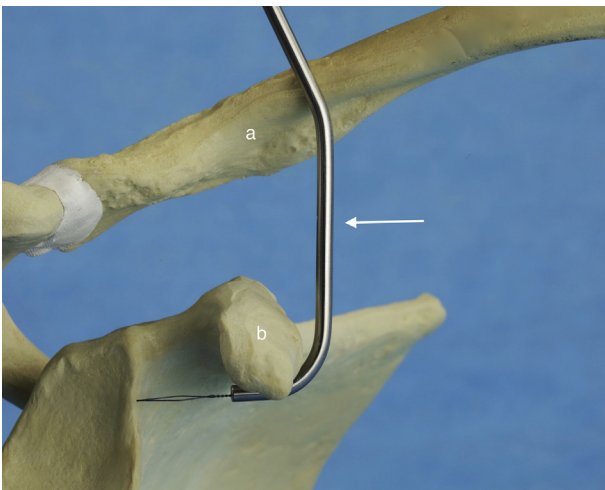


**Fig 1.** The anterior graft limb (A) replaces the trapezoid ligament, whereas the dorsal limb (B) replaces the conoid ligament. The end of the dorsal tendon graft (B) is taken over the AC joint when recreating the superior AC ligament (C). The interconnecting suture (arrow). Anterior view of the reconstruction where the tendon graft circles the coracoid. Right shoulder is shown.

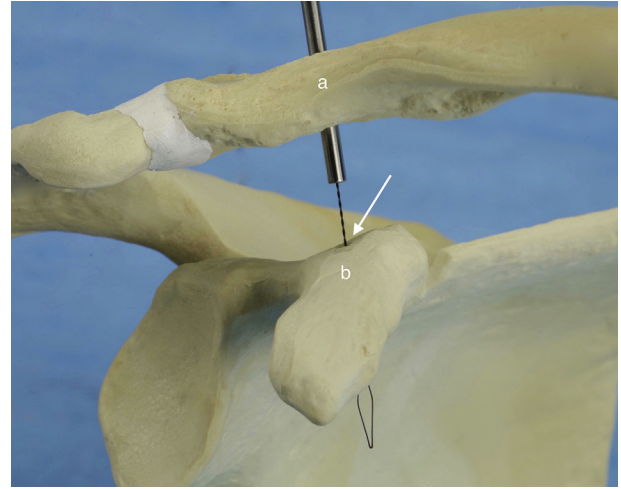
knot-hiding implants. The aim is to sustainably establish vertical and anteroposterior stability of the distal clavicle.

### Surgical Technique (With Video Illustration)

The technique includes an arthroscopic double-bundle reconstruction of the CC ligament complex and an open reconstruction of the AC ligaments using a tendon graft. A semitendinosus autograft is used. In the CC reconstruction, the tendon graft circles the coracoid, whereas a no. 5 interconnecting suture is passed through the clavicle and the coracoid. The anterior graft



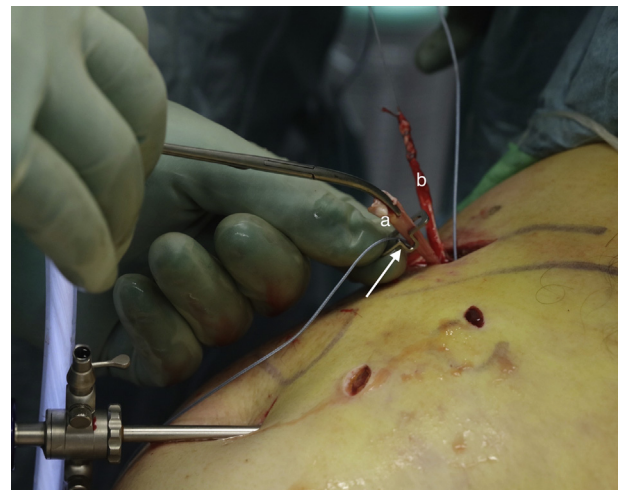
**Fig 2.** To pass suture of the graft around the coracoid, a Curved Lasso Guide is used. The guide (arrow) is positioned in front of the clavicle (A) and medial to the coracoid (B). Anterior view, right shoulder is shown.



**Fig 3.** The passing suture for the no. 5 interconnecting suture is taken through the clavicular (A) and coracoid (B) drill holes using a Straight Lasso Guide (arrow). A nitinol wire loop is pushed through the drill holes to retrieve the passing suture. Anterior view, right shoulder is shown.

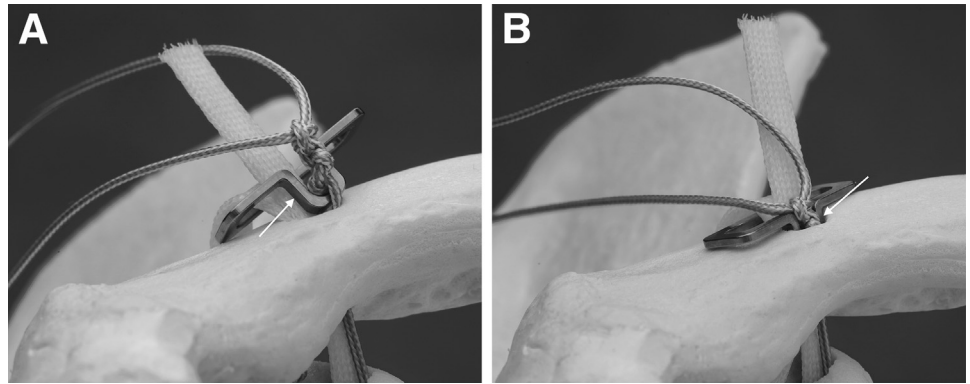
limb projects superiorly and replaces the trapezoid ligament, whereas the dorsal limb of the graft is wrapped around the dorsal edge of the clavicle to reconstruct the conoid ligament.

After tying and suturing the graft ends together, the dorsal end of the tendon graft is taken over the AC joint to reconstruct the AC ligaments and capsule (Fig 1). Supportive fixation of the reconstruction is achieved by connecting a Clavicular Clip (CC-Clip; Turku, Finland) to a Subcoracoid Clip (CC-Clip) using a strong doubled no. 5 nonabsorbable suture. The tendon graft shares the same clavicular drill hole with the suture.



**Fig 4.** The other end of a no. 5 suture and the anterior graft limb (A) are slipped through the Clavicular Clip eyelet (arrow). The posterior graft limb (B). Anterolateral view, right shoulder is shown.

**Fig 5.** (A) An interconnecting suture knot was made in the clip loop (arrow). Anterior view, right shoulder is shown. (B) The clip loop was allowed to sink into the clavicular drill hole (arrow) to hide the knot. Anterior view, right shoulder is shown.



The patient is placed in the beach chair position, and a standard 30° arthroscope is used for the procedure. The technique includes 5 portals: posterior, lateral, anterolateral anterior, and clavicular. Arthroscopy is initiated through the posterior portal, and the lateral portal is positioned by inserting a needle in front of the long-head biceps tendon while aiming at the proximal coracoid. The coracoid neck is exposed through the gap. After good access is established to the coracoid neck area, the arthroscope is moved to the lateral portal with the help of a switching stick.

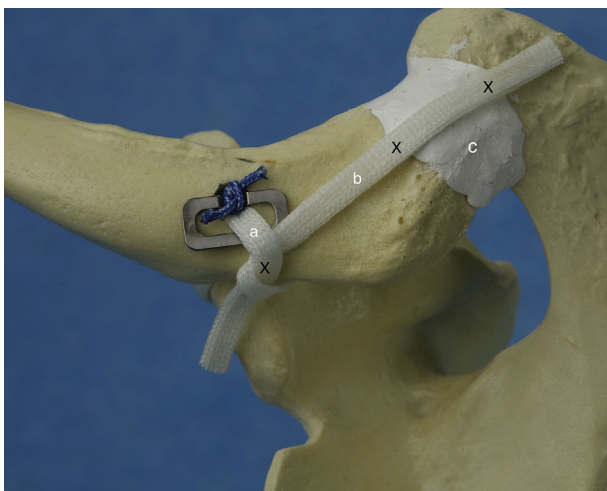
During the reconstruction, the camera is located in the lateral portal. The anterolateral and anterior portals are opened using a needle pointing to the coracoid neck. Debridement and sufficient exposure are conducted around the coracoid and clavicle. A longitudinal incision is made over the clavicle, and its superior surface is exposed for drilling. A tissue passageway is

bluntly made behind the clavicle for subsequent passing of the graft using a crile.

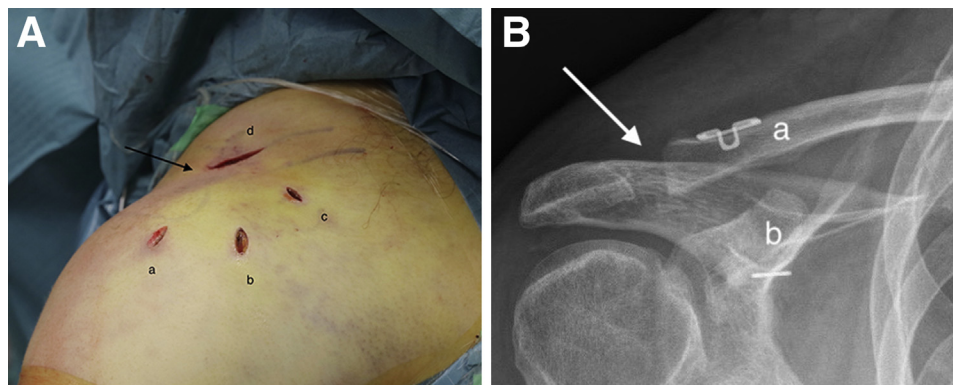
A 2.4-mm guide pin is drilled through the clavicle and the coracoid using a drill guide. The tip of the guide pin must be secured so that it is not driven too deeply. The clavicular drill hole is then widened to 5.5 mm. A nitinol lasso is passed under the coracoid using a Curved Lasso Guide (CC-Clip) that is positioned in front of the clavicle (Fig 2). The distal end of the lasso is taken to the anterolateral portal. The proximal end of the lasso wire is picked up through the clavicular drill hole. The lasso is used for the passing suture of the tendon graft. The tendon graft is then pulled through the clavicular drill hole and around the coracoid. The distal end of the graft limb is pulled to the clavicular wound behind the clavicle with the help of a crile.

Next, the passing suture for the interconnection suture is taken through the clavicular and coracoid drill holes with the help of the straight lasso guide and a nitinol lasso (Fig 3). The double-folded interconnecting suture is then pulled through the clavicular and coracoid drill holes and out through the anterolateral or anterior portal. A Subcoracoid Clip (CC-Clip) is attached to the suture loop and then pulled into position underneath the coracoid. The other end of the interconnecting suture and the anterior graft limb are slipped through the Clavicular Clip's eyelet (Fig 4). The dorsal graft limb is left longer. The interconnecting suture and graft limbs are left untied.

After the actual CC reconstruction is completed, the clavicular wound is extended over the AC joint. The overstretched AC joint capsule is opened along its fibers, and the distal end of the clavicle is resected with an oscillating saw. The distal clavicle is carefully mobilized so that it will be easy to reduce. With the CC reconstruction in place, the clavicle is repositioned with support from the elbow. The repositioning is checked under visual control. The interconnecting suture and tendon graft of the CC reconstruction are tensioned.



**Fig 6.** Anterior graft limb (A). The end of the dorsal graft limb (B) was taken over the dorsal edge of the clavicle and sutured to the anterior graft limb. The dorsal graft limb was left longer and taken over the AC joint (C). Sites for the fixation sutures (X). Superior view, right shoulder is shown.



**Fig 7.** (A) An anterolateral view of the portals and wounds related to the CC reconstruction. Lateral (A), anterolateral (B), anterior (C), and clavicular portals (D). The clavicular portal is subsequently extended laterally over the AC joint (arrow) for the open AC capsule reconstruction. The posterior portal is not visible in this photograph. Anterolateral view, right shoulder is shown. (B) A postoperative anteroposterior radiograph of the reconstruction. Clavicular Clip (A). Subcoracoid Clip (B). AC joint (arrow). Right shoulder is shown. (AC, acromioclavicular; CC, coracoclavicular.)

The interconnecting sutures are tied into the Clavicular Clip loop using a knot pusher while allowing the knot to sink into the clavicular drill hole to hide it (Fig 5). The anterior graft limb is then tensioned, tied to the posterior graft limb, and secured with no. 2 nonresorbable sutures. When the CC reconstruction is finished, the superior AC ligament is reconstructed with the remaining dorsal end of the tendon graft. The graft end is sutured over the AC joint, and the AC

capsule is then plicated tightly over it with interrupted no. 1 resorbable sutures (Fig 6). The arthroscopic portals are closed with interrupted sutures, whereas the clavicular wound is closed in layers (Fig 7, Video 1).

### Postoperative Treatment

An arm sling is worn by the patient for 6 weeks. Light rotatory movements and passive arm lifting are allowed within their limits of pain. The sling is removed after

**Table 1.** Tips and Tricks

	Pearls	Pitfalls
Portals	It is important to have the portals in the right places—always use needles.	A displaced portal—a notable problem.
Posterior portal	The surgery is initiated through the standard posterior portal.	Check additional trauma: labrum, supraspinatus tendon.
Lateral portal	Place a needle in front of the biceps tendon, aiming at the coracoid neck.	Right lateral portal positioning is essential.
Lateral portal	Use a switching stick when changing the arthroscope to the lateral portal.	Makes the move easy.
Anterolateral and anterior portals	Mark the portals with a needle aiming at the coracoid neck.	A good access to the coracoid neck area.
Clavicular portal	Create an access to the coracoid for the Curved Lasso Guide anteriorly to the clavicle. Extend the wound medial enough.	An awkward position of the guide makes it difficult.
Clavicular portal	Create a soft-tissue channel posterior to the clavicle to the coracoid neck area.	A crile is practical instrument for retrieving the passing suture of the graft.
Passing the graft	Pull the passing suture of the graft first to the clavicular portal and then pull the graft.	The graft does not usually slide well in the suture passer eyelet.
Extending the clavicular wound laterally	Do the wound extension only after the CC reconstruction is assembled.	A wound extended too early leaks the fluid out during the arthroscopy.
Tying the interconnecting suture	The mobilization of the distal clavicle first and only then tensioning and tying of the interconnecting suture and graft.	If the distal clavicle is already fixed, it is impossible to be correctly resected and mobilized.
Assembling the Clavicular Clip	All of the graft must be in its place before snapping the Clavicular Clip into the clavicular drill hole.	The clip fits tightly and it is difficult to pass anything through the drill hole once it is in place.
Knot tying	Use the knot pusher. It fits into the clip loop.	It is easier to make the knots tight enough.

CC, coracoclavicular.

6 weeks, but active rehabilitation will not begin until 8 weeks after surgery to provide enough time for recovery. Return to heavy labor is allowed 3 to 4 months after surgery, whereas overhead activity and sports can be resumed at 6 months.

### Discussion

The advantages of this technique include favorable and long-lasting results. It is also a safe procedure, and patient age is not an issue. However, there are a few pitfalls in the technique, and it is recommended that the given guidelines be followed in the right order (Table 1). An interconnecting suture or tape is often used as the only restraint to repair the unstable distal clavicle. However, it is foreign material that will most likely fail at some point, and there is a great risk for the clavicle becoming unstable again. Therefore, the use of a tendon graft is important to achieve a permanently stable outcome in chronic AC separations. It has been shown that reconstructing both the CC and AC ligaments give the best results.<sup>7,8</sup> The CC reconstruction is practical to conduct arthroscopically while open AC reconstruction provides extra anteroposterior stability. The clavicular clip provides good infection and foreign object control on the clavicle. The reduction of the distal clavicle must be tension free. If the distal clavicle is forced into place, too much strain is transferred to the reconstruction, and it will fail. Furthermore, a chronically dislocated distal clavicle is no longer normal. Therefore, distal clavicle resection should be performed and freed from surrounding scar attachments and trapezius-muscle interpositions.

This technique requires clavicular and coracoid drill holes. A falsely positioned drill hole leads to a fracture. Drill holes always are a risk, and their proper positioning is extremely important. The use of the semitendinosus autograft also induces additional morbidity. Sound surgical technique is not the only important consideration. Among the limitations is that successful surgery requires careful patient selection. For example, this procedure is not recommended for heavy smokers. It is also imperative that the postoperative

treatment protocol be followed meticulously. The forces between the clavicle and coracoid may be very high, and the tendon graft must be well integrated into place before rehabilitation begins. The arthroscopic part of the reconstruction is not technically difficult for an experienced arthroscopic shoulder surgeon. For success, it is essential to achieve a tension-free reduction of the distal clavicle and to provide sufficient recovery time postoperatively.

### References

1. Lee S, Bedi A. Shoulder acromioclavicular joint reconstruction options and outcomes. *Cur Rev Musculoskelet Med* 2016;9:368-377.
2. Kibler WB, Ludewig PM, McLure P, Michener LA, Bak K, Sciascia A. Clinical implications of scapular dyskinesis in shoulder injury: The 2013 consensus statement from the 'scapular summit'. *Br J Sports Med* 2013;47:877-885.
3. Millett PJ, Horan MP, Warth RJ. Two-year outcome after primary anatomic coracoclavicular ligament reconstruction. *Arthroscopy* 2015;31:1962-1973.
4. North AS, Wilkinson T. Surgical reconstruction of the acromioclavicular joint: Can we identify the optimal approach? *Strategies Trauma Limb Reconstr* 2018;13:69-74.
5. Ranne J, Kainonen TU, Kosola JA, et al. Arthroscopic coracoclavicular ligament reconstruction using graft augmentation and titanium implants. *Arthrosc Tech* 2018;7:e465-471.
6. Ranne JO, Kainonen TU, Lehtinen JT, et al. Arthroscopic coracoclavicular ligament reconstruction of chronic acromioclavicular dislocations using autogenous semitendinosus graft: A two-year study of 58 patients. *Arthrosc Sports Med Rehabil* 2020;2:e7-e15.
7. Moatshe G, Kruckeberg BM, Chahla J, et al. Acromioclavicular and coracoclavicular ligament reconstruction for acromioclavicular joint instability: A systematic review of clinical and radiographic outcomes. *Arthroscopy* 2019;34:1979-1995.
8. Pühringer N, Agneskirchner J. Arthroscopic technique for stabilization of chronic acromioclavicular joint instability with coracoclavicular and acromioclavicular ligament reconstruction using gracilis tendon graft. *Arthrosc Tech* 2017;6:e175-e181.